



# Three-Dimensional Endoscopy-Assisted Excision and Reconstruction for Metastatic Disease of the Dorsal and Lumbar Spine: Early Results

Sergey Lyulin, PhD, Pavel Balaev, PhD\*, Koushik Narayan Subramanyam, MS<sup>†</sup>,  
Denis Ivliev, MS<sup>‡</sup>, Abhishek Vasant Mundargi, DNB<sup>†</sup>

*Department of Neurosurgery, Ural State Medical University of the Ministry of Health of the Russian Federation, Yekaterinburg,*

*\*Department of Oncology, Ural State Medical University, Ministry of Health of the Russian Federation, Yekaterinburg, Russia*

*<sup>†</sup>Department of Orthopaedics, Sri Sathya Sai Institute of Higher Medical Sciences, Puttaparthi, India*

*<sup>‡</sup>Department of Neurosurgery, Smolensk State Medical University of the Ministry of Health of the Russian Federation, Smolensk, Russia*

**Background:** The aim of this study was to explore the role of three-dimensional (3D) endoscopy in surgical management of metastatic disease of the dorsal and lumbar spine.

**Methods:** This is a prospective study on 33 patients (15 men and 18 women, mean age of  $61.6 \pm 8.9$  years) with biopsy-proven metastatic disease of the spine managed by sequential/staged posterior decompression-stabilization, followed by 3D endoscopy-assisted anterior corpectomy and stabilization with a mesh cage. All patients had significant extradural compression or spinal instability or both. Sixteen patients had neurological deficits. Visual analog scale (VAS), Frenkel grade (neurological deficits), Karnofsky performance status scale, and the 36-item short-form health survey (SF-36) were used for assessment preoperatively and at 3, 6, and 12 months from surgery.

**Results:** At a mean follow-up of  $1.7 \pm 0.7$  years from surgery, 18 patients were alive. VAS showed significant improvement at the latest follow-up compared to preoperative levels (4.39 vs. 6.61,  $p = 0.001$ ). Karnofsky status did not show any significant improvement. Frenkel grade improved in 5 patients, deteriorated in 4 patients, and remained unchanged in 24 patients. Regarding SF-36 parameters, general health showed deterioration, but role functioning—physical, role functioning—emotional, social functioning, and body pain showed statistically significant improvement. There was no change in physical health, viability, and mental health. Subjectively the surgeons felt better depth perception and smoother surgical experience with the 3D optics technology. The only complication was delayed wound healing in three patients who had a previous history of radiotherapy to the surgical site.

**Conclusions:** 3D endoscopy is a valuable tool in the management of metastatic spinal disease requiring excision and reconstruction using the combined posterior and anterior approaches. These early results warrant confirmation with more data and longer follow-ups.

**Keywords:** *Spinal metastasis, Spine endoscopy, Three dimensional endoscopy, Thoracoscopy, Corpectomy*

Received January 13, 2021; Revised August 3, 2021;

Accepted September 27, 2021

Correspondence to: Koushik Narayan Subramanyam, MS

Department of Orthopaedics, Sri Sathya Sai Institute of Higher Medical Sciences, Prashanthigram, Puttaparthi, Andhra Pradesh 515134, India

Tel: +91-9491629620

E-mail: drkoushik@hotmail.com

Metastatic involvement of the spine is one of the most life-threatening events in patients with systemic malignancy. Bone is the third most common site of metastatic spread and the spine is the most commonly affected skeletal structure. Ten to twenty percent of patients with spine metastasis undergo spinal cord compression, which results in serious compromise of their quality of life.<sup>1)</sup> The aim of treatment of spinal metastasis in these patients is improve-

ment of life expectancy to the extent possible by avoiding major complications such as paraplegia.<sup>2)</sup> In addition, treatment also is aimed at improvement of the quality of life and preservation of mental health, spinal stability, and neurological function.<sup>3)</sup>

Recently, less aggressive and less invasive surgical approaches are gaining popularity in metastatic surgery in view of reducing perioperative morbidity and mortality. The addition of stereotactic radiosurgery and stereotactic body radiotherapy has reduced the amount of tumor removal required. A modern concept of “separation surgery” combines minimally invasive circumferential excision of a tumor around the spinal cord, allowing single-fraction high-dose radiotherapy of the residual disease, and minimally invasive stabilization of the spine to preserve stability. All these approaches are aimed at reducing the surgical exposure, duration, blood loss, and overall impact on perioperative morbidity.<sup>4)</sup>

There are limited reports on the use of video-assisted endoscopy in management of metastatic spine disease.<sup>5-7)</sup> The conventional video endoscopic approach poses challenges of three-dimensional (3D) orientation and depth perception when projected onto a two-dimensional (2D) monitor. This problem is overcome by the use of 3D visualization. Three-dimensional endoscopic optics uses two cameras to simulate the different perspectives of the right eye and left eye, creating the illusion of spatial depth. Surgeons use 3D spectacles and are enabled with optimal orientation and improved hand-eye coordination. A limited number of reports of 3D endoscopy in spine surgery are available in the context of spine trauma surgery.<sup>8-10)</sup> To our knowledge, this technique has not been reported for the management of spinal metastases. In this context, we undertook a prospective observational study to understand the role of 3D endoscopy in management of spinal metastases that need surgical intervention.

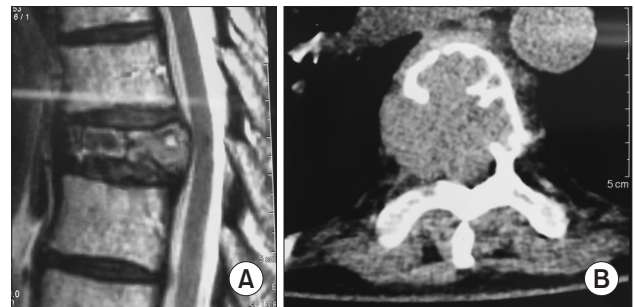
## METHODS

The prospective observational study was commenced from the point when we started applying 3D endoscopy in the management of metastatic spinal disease. All consecutive patients who were operated for spinal metastasis with the use of 3D imaging endoscopy between July 2017 and June 2019 with at least 1 year of follow-up were included in the study. The study was approved by the Institutional Ethics Committee FGBOU VO-Ural State Medical University, Ministry of Health of the Russian Federation (IRB No. 4/2021). Written informed consent was obtained from all patients included in the study. In the consent form, all pa-

tients gave their consent for their images and other clinical information to be used in the study and for scientific publications. The patients were informed that their names and initials would not be published and due efforts would be made to conceal their identity, but anonymity could not be guaranteed.

All patients were treated by the same team of surgeons using a standard surgical approach and a technique. The technique involved two-stage posterior decompression, followed by anterior decompression and stabilization. It was at the stage of anterior surgery that 3D endoscopy was employed. Before surgery, all patients were evaluated by thorough clinical examination, plain radiography, multispiral computed tomography, and magnetic resonance imaging (MRI) (Fig. 1). Surgical intervention was planned based on evaluation of tumor prognosis by Tokuhashi score,<sup>11)</sup> spinal instability by Spinal Instability Neoplastic score,<sup>12)</sup> and epidural spinal compression by Bilsky scale.<sup>13)</sup> The patients were evaluated by a dedicated observer (PB) before surgery and at 3, 6, and 12 months from surgery according to a predefined format, which included clinical examination, plain radiography, and following evaluation score assessment: visual analog scale (VAS),<sup>14)</sup> Frenkel grade of paraplegia,<sup>15)</sup> Karnofsky performance status scale,<sup>16)</sup> and the 36-item short-form health survey (SF-36).<sup>17)</sup>

There were 33 patients, 15 men and 18 women with a mean age of  $61.6 \pm 8.9$  years. The details of the primary malignancy that resulted in spinal metastasis and clinical parameters at presentation are summarized in Table 1. The details of treatment received for primary malignancy are summarized in Table 2. The decision to operate was taken by a multidisciplinary team and the main indications for surgery were spinal cord compression that needed decom-



**Fig. 1.** Preoperative imaging of a 70-year-old male patient with a history of bronchogenic carcinoma with metastatic fracture of D9 vertebra with pain (visual analog scale score 9) and neurological deficits (Frenkel grade C). (A) Magnetic resonance imaging, sagittal section. (B) Computed tomography, axial section.

**Table 1.** Preoperative Characteristics of the Patient Cohort

Characteristic	No. of patients
Primary malignant focus	
Breast	12
Prostate	6
Gastrointestine	6
Lung	4
Kidney	2
Uterus	2
Thyroid	1
Number of spinal segments involved	
1	12
> 1	21
Spinal instability neoplastic score	
0–6	1
7–12	25
13–18	7
Epidural spinal cord compression scale (Bilsky)	
1b	2
1c	9
2	13
3	9
Tokuhashi score (predicted survival)	
0–8 (up to 6 mo)	8
9–11 (6–12 mo)	15
12–15 (more than 12 mo)	10

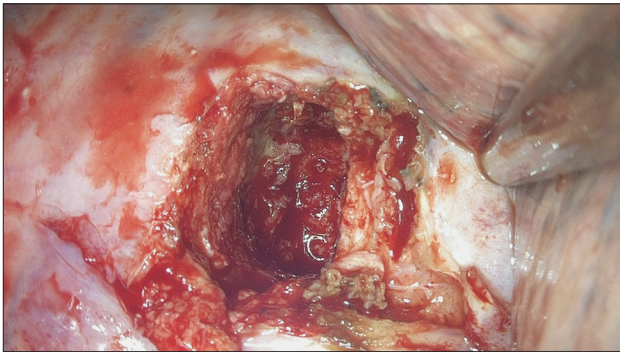
pression and spinal instability that needed stabilization. All operations followed the same protocol of posterior decompression and stabilization, followed by anterior decompression and stabilization. In 11 patients, the entire surgery could be performed on the same day. In the rest 22 patients, the posterior and anterior components of the surgery were divided into two stages, 5 to 7 days apart.

Under general anesthesia, the surgery was started with the patient in prone position and posterior exposure of the affected vertebrae extending proximally and distally. The involved posterior elements of the affected vertebrae were removed and the spine was stabilized with pedicular screws and rods (titanium) extending two to three levels

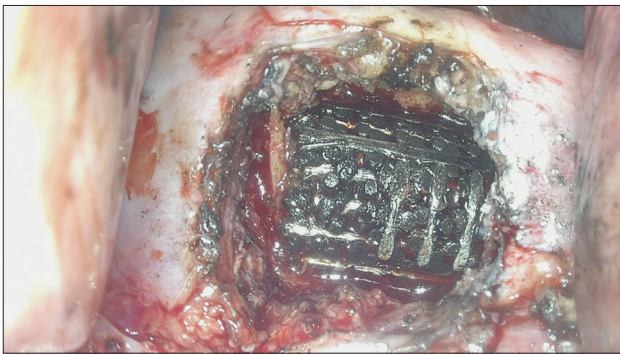
**Table 2.** Summary of Treatment Received for Primary Malignancy

Parameter	No. of patients
Surgery	
Radical surgery	14
Palliative surgery	1
No surgery	18
Radiotherapy	
Yes	23
No	10
Chemotherapy	
Yes	25
No	8

proximally and distally. The wound was closed in layers over drain. Anterior surgery was performed through right thoracoscopy till L1 level (lesions of dorsolumbar junction requiring separation of the fibers of diaphragm) and right mini-retroperitoneal endoscopy for lesions below L1. Thoracoscopy was carried out under single lung ventilation. In left lateral position, the diseased vertebra was visualized with an image intensifier and the corresponding projection on the skin was marked. There were three endoscopic ports: the dorsal along the posterior axillary line and the other two along the mid-axillary line. The area of planned excision was visualized with an endoscope. The segmental vessels were ligated and divided. The parietal pleura (in thoracoscopy) and prevertebral tissues were dissected. The anterior and lateral surfaces of the vertebral bodies with the discs above and below were exposed. The superior and inferior aspects of the vertebral body were dissected and the vertebra was removed with pendulum-like swaying movements from adjacent tissues towards the corresponding part of the spinal cord until complete removal as one block. Complete removal of metastatic disease was ensured with endoscopic visualization (Fig. 2). The anterior spinal defect was bridged with a mesh cage of appropriate size and length. The cage was packed with bone cement if the expected survival of the patient was low and with an autogenous rib graft if the expected survival was fair. In this series, 23 patients had bone cement and 10 patients had bone graft packed into the mesh cage. The mesh cage was made of titanium in 30 of our patients; in 3 patients, we implanted a carbon mesh cage to facilitate postoperative MRI and early diagnosis of possible recurrence (Fig. 3). Wound was closed in layers over intercostal drain after



**Fig. 2.** Three-dimensional endoscopic view of the anterior defect following posterior decompression, stabilization, and endoscopic corpectomy.



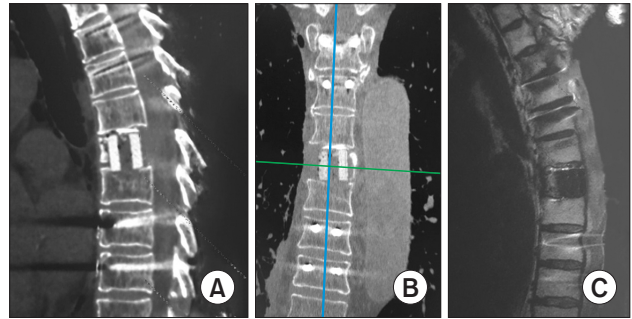
**Fig. 3.** Bridging of the defect with a carbon mesh cage.

confirming the position of the implant radiologically. All tissues removed were sent for histopathological examination. All patients could mobilize from the first postoperative day without the requirement of any brace. Patients were advised for follow-up once in 3 months for the first 2 years and every 6 months thereafter (Figs. 4 and 5).

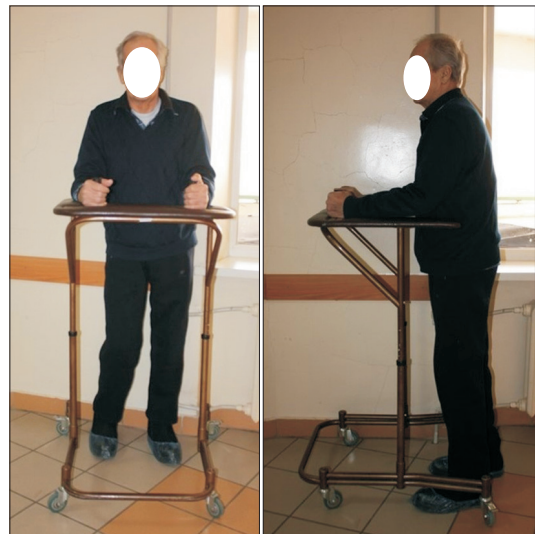The data were analyzed using IBM SPSS ver. 25 (IBM Corp., Armonk, NY, USA) predictive analytic software. Continuous variables were expressed as mean (standard deviation) and categorical variables were summarized as number. Normality of continuous variables was assessed by Kolmogorov–Smirnov test with the Lilliefors correction. The difference between preoperative and postoperative scores were assessed with paired *t*-test if the differences within all sets of paired variables were normally distributed, otherwise Wilcoxon signed-rank test was used. All tests were two-tailed and the level of statistical significance was set at  $p < 0.05$ .

## RESULTS

All patients could be followed up for at least 1 year from surgery (or till death if happened before 1 year). At the



**Fig. 4.** Imaging at 3 months from surgery. (A) Computed tomography, sagittal section. (B) Computed tomography, coronal section. (C) Magnetic resonance imaging, sagittal section.



**Fig. 5.** Clinical results at 3 months from surgery (visual analog scale score 6, Frenkel grade D). The patient was ambulant till he succumbed to progressive metastatic disease at 10 months from surgery.

mean duration of  $1.7 \pm 0.7$  years from surgery, 18 patients were alive and 15 patients succumbed to the disease. The mean duration of survival of the 15 patients who died was  $5.54 \pm 2.82$  months from surgery. Pain, performance, and quality of scores were compared between preoperative values and the values at 1-year follow-up for the patients who survived beyond 1 year. For the patients who died before 1 year, the value at the latest follow-up was taken as the final value to look for comparison. Pain scores showed statistically significant improvement compared to preoperative values (VAS, 4.39 vs. 6.61;  $p = 0.001$ ), whereas Karnofsky performance status scale did not show any improvement. Frenkel grade of neurological function remained unchanged for 24 patients between preoperative assessment and final follow-up. It improved by 1 grade for 5 patients and deteriorated by 1 grade for the rest 4 patients. Among

SF-36 parameters, general health showed deterioration, which was statistically significant. This reflects the systemic progression of the disease, especially in the patients who died. The parameters including role-based functioning–physical, role-based functioning–emotional, social functioning, and body pain showed statistically significant improvement compared to preoperative levels. The improvement of the other parameters–physical health, viability, and mental health–was marginal and not statistically significant (Table 3). There were no complications specific to the surgery or implant either in the postoperative period or during follow-up. Fourteen of our patients had history of radiotherapy on the spinal level operated. Three of these patients had delayed healing of the surgical wound with no evidence of infection.

## DISCUSSION

The spine is one of the most common sites of metastatic disease in malignancies. The objective of spine surgery in metastases is mostly palliative. Surgeons aim to maintain or improve the patient's quality of life during the remainder of their survival by reducing pain and preserving ambulatory function. The development of less invasive surgical techniques and newer adjuvant therapies has made the role of surgery more significant in the present times. Minimizing morbidity and shortening recovery time are

important in patients with spinal metastasis because of limited life spans. Various minimal access modalities (anterior and posterior) have been described in literature.<sup>18)</sup> Studies comparing less aggressive and conventional surgical approaches in spine metastases have suggested that less aggressive approaches are better or at least equivalent to conventional approaches in terms of surgical morbidity and mortality.<sup>19)</sup> However, the quality of evidence available is deemed poor that no definite conclusions can be arrived at.<sup>20)</sup>

We reported here a series of carefully selected patients with spinal metastasis where combined posterior and anterior decompression was recommended by our multidisciplinary team. In patients with solitary metastasis, corpectomy and reconstruction was done through the endoscopic route, whereas in patients with multilevel metastases, decompression and stabilization of the anterior spine were the objectives. Though “posterior alone” approach has been described for excision and reconstruction, this is considered technically very challenging with high risk of complications.<sup>21)</sup> We believe that a successful resection needs a combination of anterior and posterior approaches.<sup>22)</sup> With the view to reducing the morbidity of surgery, we substituted the anterior component of the open surgery with endoscopy. Being more surgeon friendly, we adopted 3D optics in endoscopy. To our knowledge, this is the first report of this technology in spinal metastasis.

**Table 3.** Comparison of Outcome Measures between Preoperative and at Latest Available Follow-up

Variable	Preoperative	Follow-up	p-value
Visual analog scale*	6.61 ± 2.42	4.39 ± 2.12	0.001 <sup>‡</sup>
Frenkel grade (C : D : E)	1 : 15 : 17	1 : 14 : 18	-
Mean Karnofsky performance status scale <sup>†</sup>	73.94 ± 16.39	72.52 ± 15.81	0.48
SF-36 parameter			
General health*	48.06 ± 18.40	34.74 ± 14.66	0.003 <sup>‡</sup>
Physical functioning*	22.73 ± 25.02	25.64 ± 21.38	0.564
Role-based functioning; physical <sup>†</sup>	6.06 ± 14.01	22.91 ± 30.13	0.015 <sup>‡</sup>
Role-based functioning; emotional*	12.21 ± 27.53	31.73 ± 39.37	0.038 <sup>‡</sup>
Social functioning*	42.64 ± 13.63	53.64 ± 22.68	0.034 <sup>‡</sup>
Body pain <sup>†</sup>	25.09 ± 18.22	41.58 ± 19.44	0.001 <sup>‡</sup>
Viability*	32.12 ± 22.40	34.65 ± 18.38	0.574
Mental health*	46.18 ± 17.94	50.24 ± 14.64	0.343

Values are presented as mean ± standard deviation.

SF-36: 36-item short-form health survey.

\*By paired t-test. <sup>†</sup>By Wilcoxon signed-rank test. <sup>‡</sup>Statistically significant.

We subjectively felt that the addition of 3D optics added to the value and utility of conventional 2D endoscopy. We were very satisfied with 3D image quality and stereoscopic views, which facilitated smooth surgery. Depth perception was much better compared to 2D endoscopy. This facilitated identification and careful handling of vital structures. Even if one of the cameras of the video portal got blurred, 2D vision was still preserved due to the other camera. This was unlike 2D endoscopy where there is no vision if the single camera got blurred, for example, due to blood spots. Cleaning the video portal quickly restored the 3D visualization.

This study has numerous limitations. The first would be the small sample size. A small number of patients were indicated for excision surgery. The second limitation is assessment bias as one of the members of the surgical team himself (PB) evaluated the results. This could be reduced to a good extent by employing a single dedicated assessor. We also acknowledge that the expertise and equipment involved in the strategy presented is not easily available. What we have presented is our preliminary experience. A longer follow-up and data on more patients from more centers and prospective comparative studies are needed to make definite conclusions regarding the role of 3D endoscopy in management of metastatic vertebral tumors. What we intended was to share our experience with 3D visualization. We are unable to opine that our technique is superior to 2D endoscopy or conventional open surgery since our outcome measures do not support

such a claim. Having had the experience, equipment, and expertise related to 3D technology and having felt it to be an excellent value addition in our armamentarium, we thought it would be unethical to design randomized studies involving 2D visualization or open surgery and explore if 3D technology would be superior.

We concluded that 3D endoscopy is of excellent value addition to management of metastatic spinal disease that needs excision and reconstruction using the combined posterior and anterior approaches with regard to outcome and safety. However, these early results need to be validated with a longer follow-up and studies from more centers.

## CONFLICT OF INTEREST

No potential conflict of interest relevant to this article was reported.

## ORCID

Sergey Lyulin <https://orcid.org/0000-0002-2549-1059>  
 Pavel Balaev <https://orcid.org/0000-0002-2430-002X>  
 Koushik Narayan Subramanyam <https://orcid.org/0000-0001-5257-9956>  
 Denis Ivliev <https://orcid.org/0000-0002-6106-7693>  
 Abhishek Vasant Mundargi <https://orcid.org/0000-0002-5046-7034>

## REFERENCES

- Perrin RG, Laxton AW. Metastatic spine disease: epidemiology, pathophysiology, and evaluation of patients. *Neurosurg Clin N Am.* 2004;15(4):365-73.
- Kurisunkal V, Gulia A, Gupta S. Principles of management of spine metastasis. *Indian J Orthop.* 2020;54(2):181-93.
- Conti A, Acker G, Kluge A, et al. Decision making in patients with metastatic spine: the role of minimally invasive treatment modalities. *Front Oncol.* 2019;9:915.
- Joaquim AF, Powers A, Laufer I, Bilsky MH. An update in the management of spinal metastases. *Arq Neuropsiquiatr.* 2015;73(9):795-802.
- Molina CA, Gokaslan ZL, Sciubba DM. A systematic review of the current role of minimally invasive spine surgery in the management of metastatic spine disease. *Int J Surg Oncol.* 2011;2011:598148.
- Liang Y, Liu P, Zhou XG, et al. En bloc resection with the assistance of video-assisted thoracoscopy for left lower lung cancer invading thoracic vertebrae and rib: a case report. *Orthop Surg.* 2017;9(4):391-5.
- Stoker GE, Buchowski JM, Kelly MP, Meyers BF, Patterson GA. Video-assisted thoracoscopic surgery with posterior spinal reconstruction for the resection of upper lobe lung tumors involving the spine. *Spine J.* 2013;13(1):68-76.
- Smits AJ, Deunk J, Bloemers FW. Three-dimensional thoracoscopic surgery for spine fractures: a technical report with first results and experiences. *Global Spine J.* 2018;8(8):821-6.
- Jacobs C, Ploger MM, Scheidt S, et al. Three-dimensional thoracoscopic vertebral body replacement at the thoracolumbar junction. *Oper Orthop Traumatol.* 2018;30(5):369-78.
- Jacobs C, Ploeger MM, Scheidt S, et al. 3-D optics for thoracoscopic vertebral body replacement: essential technical

- progress or just nice to have? *Z Orthop Unfall*. 2019;157(1):35-41.
11. Pelegrini de Almeida L, Vidaletti T, Martins de Lima Cecchini A, et al. Reliability of Tokuhashi Score to predict prognosis: comparison of 117 patients. *World Neurosurg*. 2018;111:e1-6.
  12. Versteeg AL, Verlaan JJ, Sahgal A, et al. The spinal instability neoplastic score: impact on oncologic decision-making. *Spine (Phila Pa 1976)*. 2016;41 Suppl 20:S231-7.
  13. Bilsky MH, Laufer I, Fourney DR, et al. Reliability analysis of the epidural spinal cord compression scale. *J Neurosurg Spine*. 2010;13(3):324-8.
  14. Flynn D, van Schaik P, van Wersch A. A comparison of multi-item Likert and Visual Analogue Scales for the assessment of transactionally defined coping function. *Eur J Psychol Assess*. 2004;20(1):49-58.
  15. Frankel HL, Hancock DO, Hyslop G, et al. The value of postural reduction in the initial management of closed injuries of the spine with paraplegia and tetraplegia. I. Paraplegia. 1969;7(3):179-92.
  16. Friendlander AH, Ettinger RL. Karnofsky performance status scale. *Spec Care Dentist*. 2009;29(4):147-8.
  17. Lins L, Carvalho FM. SF-36 total score as a single measure of health-related quality of life: scoping review. *SAGE Open Med*. 2016;4:2050312116671725.
  18. Chang SY, Mok S, Park SC, Kim H, Chang BS. Treatment strategy for metastatic spinal tumors: a narrative review. *Asian Spine J*. 2020;14(4):513-25.
  19. Spiessberger A, Arvind V, Gruter B, Cho SK. Thoracolumbar corpectomy/spondylectomy for spinal metastasis: a pooled analysis comparing the outcome of seven different surgical approaches. *Eur Spine J*. 2020;29(2):248-56.
  20. Zuckerman SL, Laufer I, Sahgal A, et al. When less is more: the indications for MIS techniques and separation surgery in metastatic spine disease. *Spine (Phila Pa 1976)*. 2016;41(Suppl 20):S246-53.
  21. Hsieh PC, Li KW, Sciubba DM, Suk I, Wolinsky JP, Gokaslan ZL. Posterior-only approach for total en bloc spondylectomy for malignant primary spinal neoplasms: anatomic considerations and operative nuances. *Neurosurgery*. 2009;65(6 Suppl):173-81.
  22. Missenard G, Bouthors C, Fadel E, Court C. Surgical strategies for primary malignant tumors of the thoracic and lumbar spine. *Orthop Traumatol Surg Res*. 2020;106(1S):S53-62.